

Gross and histological comparison of hydatid cyst infection in livers of sheep and cows

M.A.H. Al Se'adawy.

Coll. of Scie./ Unive.of Al-Muthanna

M. J.A.AIKaled

Coll. of Vet.Med./ Unive. of AlQadisiya

Abstract

3 samples of fertile hydatid cysts and 3 other sterile were collected from sheep liver and 3 samples of sterile hydatid cysts from cows liver. Infected liver samples with hydatid cyst were obtained from meat seal shops in AL-Muthanna province in December 2010, then measured dimensions of cysts and calculated quantity of hydatid fluid and viability of protoscolices by staining with eosin stain then examining under light microscope of 40x. petechial hemorrhage and paleness around cysts were important gross lesions in sheep in addition to calcification in cow hydatid cysts, on other hand the histological lesions were thickened fibrous layer and severe necrosis with infiltrations of eosinophils and extensive calcification in cows liver. There was significant effect of amount of hydatid cyst, thickness of fibrous layer and thickness of necrotic layer.

Introduction

Hydatid disease due to cystic echinococcosis is one of the most important public health and economic problems in different countries including Iraq. Hydatid disease is a zoonosis caused by the tapeworm of *Echinococcus spp.* These species include *E. granulosus*, *E. multilocularis*, *E. vogeli* or *E. oligarthrus*¹. These parasites live as a small intestinal tapeworm of dogs and occasionally other carnivores². Their larval form causes hydatidosis in domestic animals and man³. The shedding of gravid proglottids or eggs in the feces occurs within 4–6 weeks after infection of the definitive host. Ingestion of eggs by intermediate host animals (sheep, cattle, goats, horses, camels) or human results in the release of an oncosphere into the gastrointestinal tract, which then migrates to primary target organs such as liver and lungs, and less frequently to other organs⁴. Usually the fully mature metacestode (i.e. hydatid cyst) develops within several months or years. The hydatid disease is prevalence where livestock is raised in association with dogs.

Those endemic areas include Australia, Latin America, Europe, Africa and the Middle East⁵. Liver is the most common site of cystic development, in over 90% of liver cysts; the oncosphere is trapped in the central veins of the hepatic lobules and the resultant cyst may be deep or superficial and it causes compression of the liver cells which can lead to biliary stasis and cholangitis⁶. The cyst may present as a liver abscess and large cyst can produce localized or diffuse hepatomegaly⁷. Local pathological effects depend on the site of the hydatid cyst; ruptured liver cyst through the diaphragm can produce a pleural effusion or bronchobiliary fistula⁸. The parasite destroys the liver parenchyma, bile ducts and blood vessels resulting in symptoms of biliary obstruction, portal hypertension and necrosis of the central portion of the cyst with abscess formation. Growth of the germinal membrane into blood vessels produces metastasis to almost any organ, but they are more commonly found in the lungs and brain⁹.

Materials and Methods

3 samples of fertile hydatid cysts and 3 other sterile were collected from sheep liver and 3 samples of sterile hydatid cysts from cow's liver. Infected liver samples with hydatid cysts are obtained from meat seal shops in AL-Muthanna province in

December 2010 and put the samples in cleaned container and transferred to laboratory. In first time important gross pathological changes recorded on infected samples like petechial hemorrhage, infiltrations, bloody patches around cysts

and calcifications , Then measured (length and width) of cysts and calculated the quantity of hydatid fluid and collected in clean and disinfected containers. Hydatid fluid was aspirated from cyst by syringe and protoscolices were scraped from sides of germinal layer and putting in test tubes then centrifuged at 2500 rpm for 5 minute, the supernatant discharged and sediment used for measuring viability of protoscolices by staining with eosin stain then examining under light microscope of 40x. the red protoscolices consider dead

The samples were evaluated grossly and histology

Grossly

Sheep

Sterile cysts : petechial hemorrhage and infiltrations inflammatory cells around cysts.

Fertile cysts : blood patches , infiltrations of inflammatory cells around cysts and paleness of most areas of liver.

Cows

Sterile cysts : calcifications, blood patches and infiltrations of inflammatory cells around cysts and pale on margins of liver.Length, width and amount of fluid in sheep for sterile hydatid cysts were 5.25 centimetres(cm), 2.50 cm and 16.33 millilitres (ml) respectively while for fertile hydatid cysts were 5.50 cm, 3.50 cm and 27.80 ml respectively. In cows for sterile hydatid cysts were 5.50 cm, 2.50 cm and 8.58 ml respectively (table 1,2) (figure 1,2). The significant effect exist at $p \leq 0.05$ of amount of fluid of hydatid cysts.

Histology

Sheep:

Sterile cysts : thickened fibrous layer and sever necrosis (neuclei of hepatocytes appear in different stages of necrosis , some neuclei appear pyknotic or Karyorrhesis while other appear

while other green are alive ^{10,11}.Cysts opened carefully and noticed germinal layer which isolated in container then cutting the cyst with part of liver tissue for certain distances (1cm,2cm and 3cm) from cysts and tissues put in formalin 10 % then discharging of formalin and replaced with another formalin after one day.SAS¹² Users Guide used with Complete Randomized Design in analyzing of research data, the differences between averages were tested at $P \leq 0.05$ by Duncan¹³.

Results

karyolysis) with infiltrations of eosinophils (eosinophilia). After these layers, the normal tissue appears with normal hepatocytes and sinusoids without infiltrations of inflammatory cells (picture 5,6).

Fertile cysts : thickened fibrous layer and sever necrosis with eosinophilia and severe scattered of inflammatory cells with fibrous tissue. After these layers, the normal tissue appears with foci of inflammatory cells (picture 7,8).

Cows

Sterile cysts : Thickened fibrous layer and sever necrosis with eosinophilia and extensive calcification along hepatic tissue. The normal tissue appears with severe scattered of inflammatory cells and fibrous tissue (picture 9,10).Thickness of fibrous layer of sterile and fertile hydatid cysts in sheep and sterile cysts in cows were 47.50 micrometer, 48.42 micrometer and 93.94 micrometer respectively, thickness of necrotic layer in sheep of sterile and fertile hydatid cysts and sterile cysts in cows were 61.15 micrometer,73.17 micrometer and 45.50 micrometer respectively . The significant effect exist at $p \leq 0.05$ (table 3) (figure 3).

Table (1) length of sterile and fertile hydatid cysts in sheep and cows

	Sheep		cow	Significant level
	sterile cysts	fertile cysts	sterile cysts	
length of cysts(cm)	5.25	5.50	5.50	N.S
width of cysts(cm)	2.50	3.50	2.50	N.S

Table (2) amount of fluid of sterile and fertile hydatid cysts in sheep and cows

	Sheep		cow	Significant level
	sterile cysts	fertile cysts	sterile cysts	
amount of fluid of cysts(cm ³)	b* 16.33	a* 27.80	c* 8.58	0.05

*The different letters in the same row refer to presence of significant effect at $p \leq 0.05$.

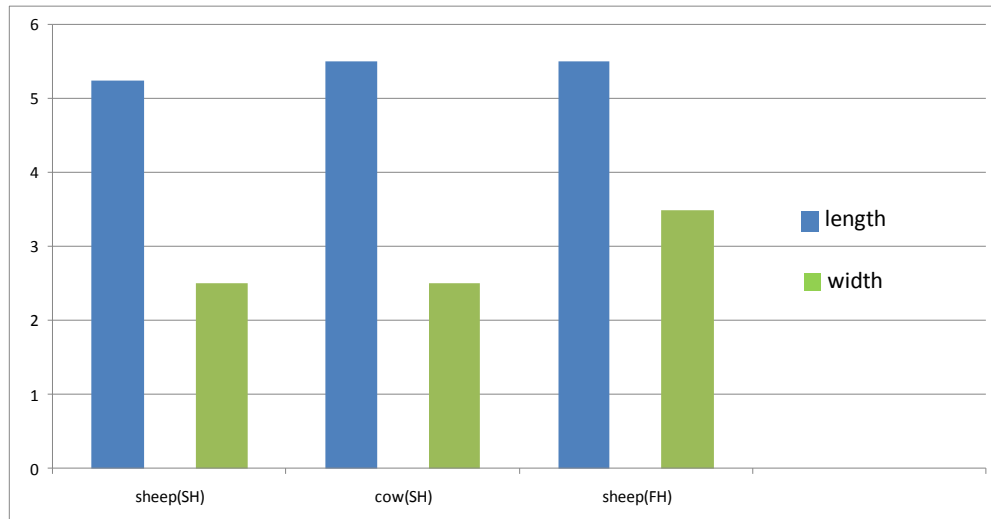
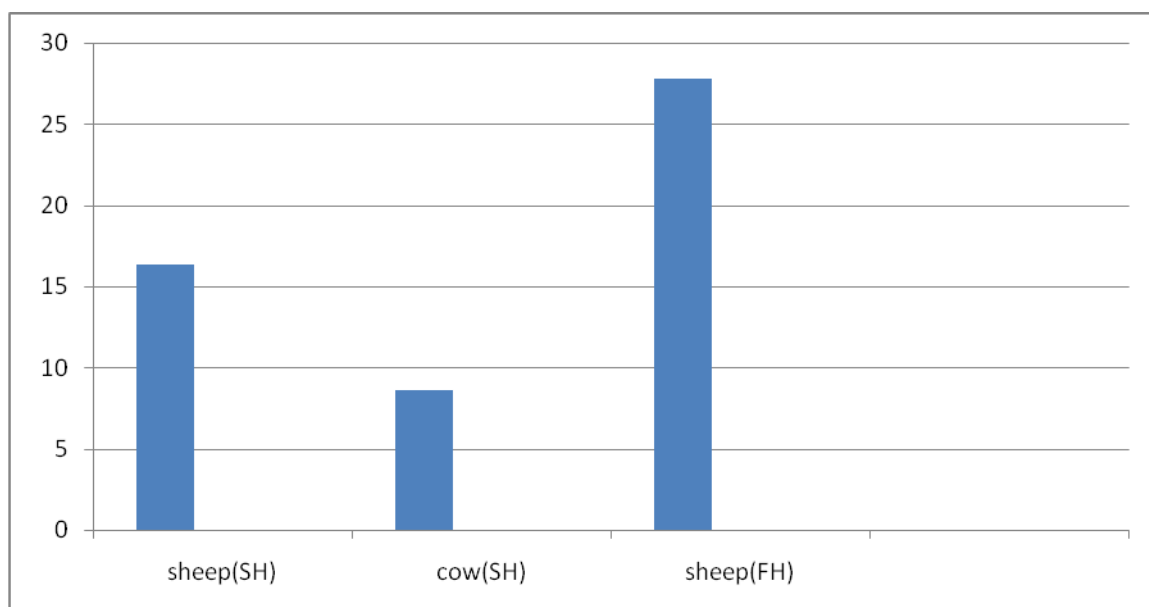


Fig. (1) length and width of sterile and fertile hydatid cysts in sheep and cows

Fig. (2) amount of fluid (cm³) of sterile and fertile hydatid cysts in sheep and cows

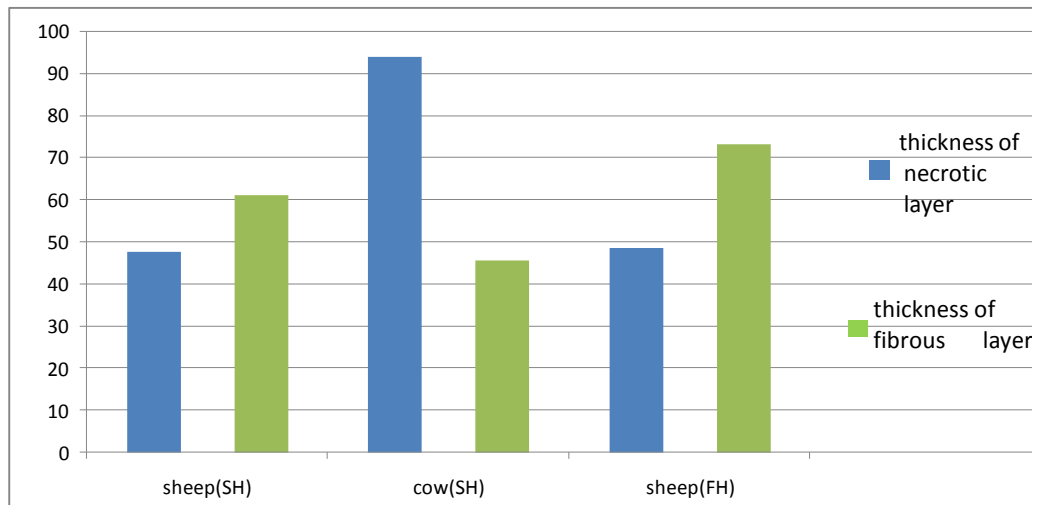
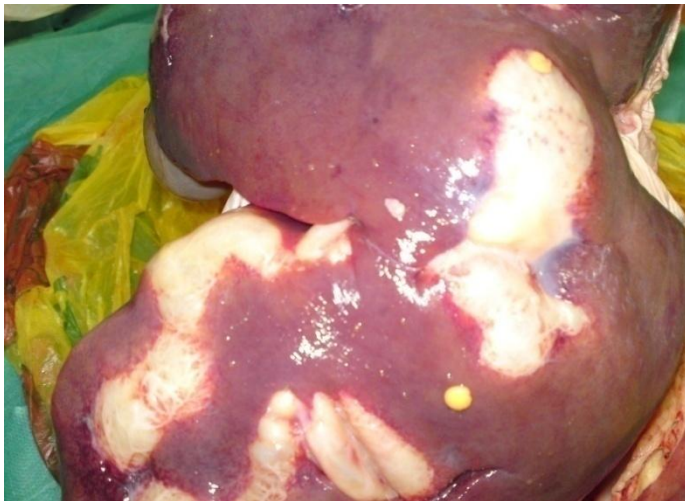
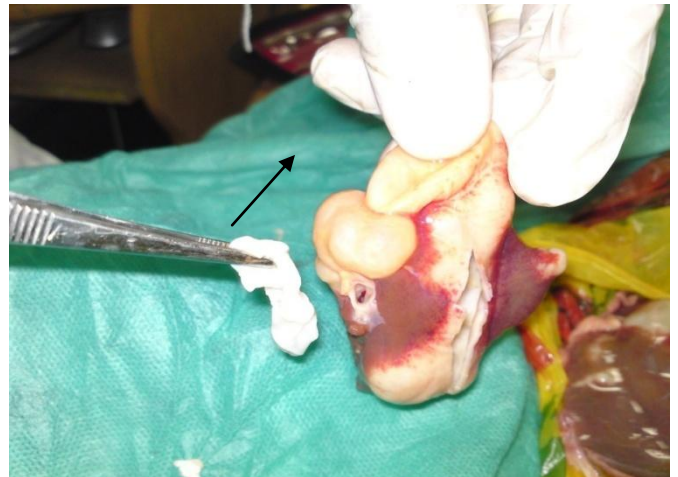
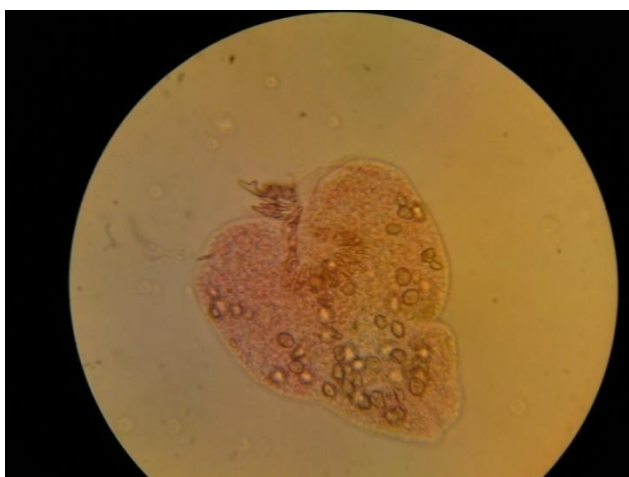
Fig. (3) thickness of fibrous layer and necrotic layer (micrometer) of sterile and fertile hydatid cysts in sheep and cows



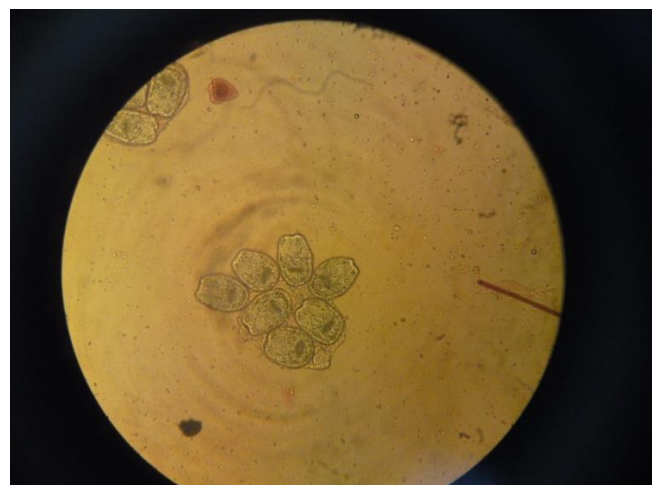Pic. (1) Liver of sheep infected with hydatid cyst



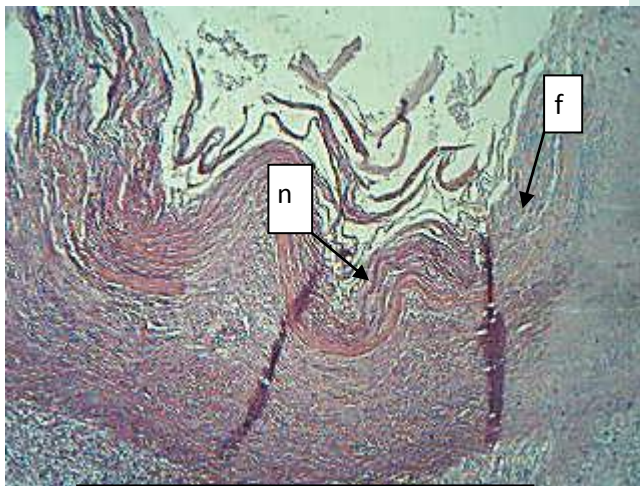
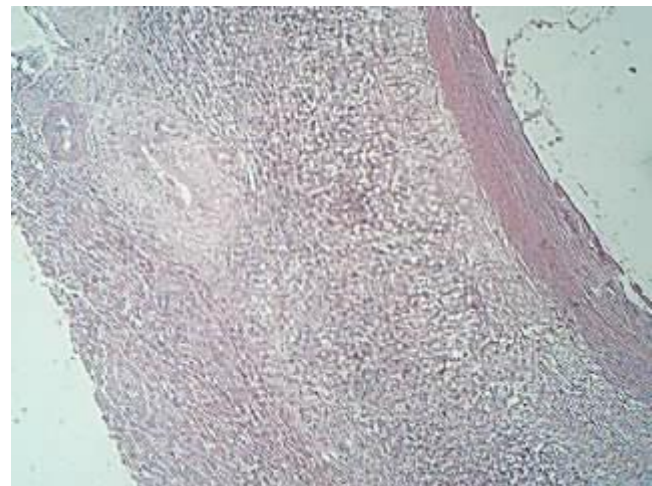
Pic. (2) Brood capsule from infected sheep liver by eosin(Red)



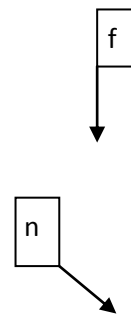
Pic. (3) Dead protoscolex Stained by eosin (Red)



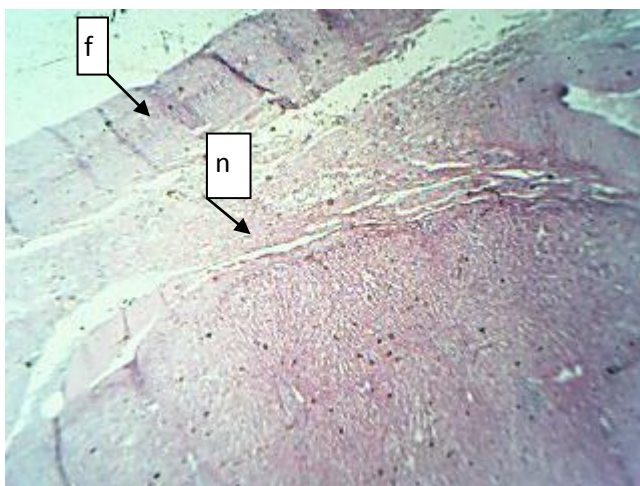
Pic(4) Alive protoscolices Stained by eosin (Green)



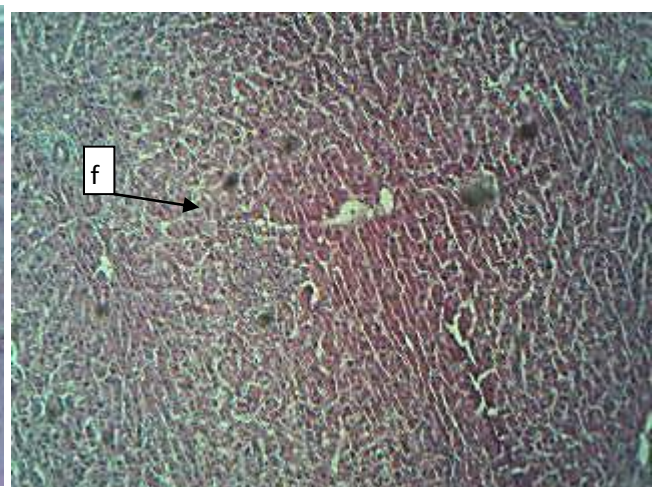
Pic. (5) thickened fibrous layer(f) and sever necrosis(n) of sterile cysts in sheep



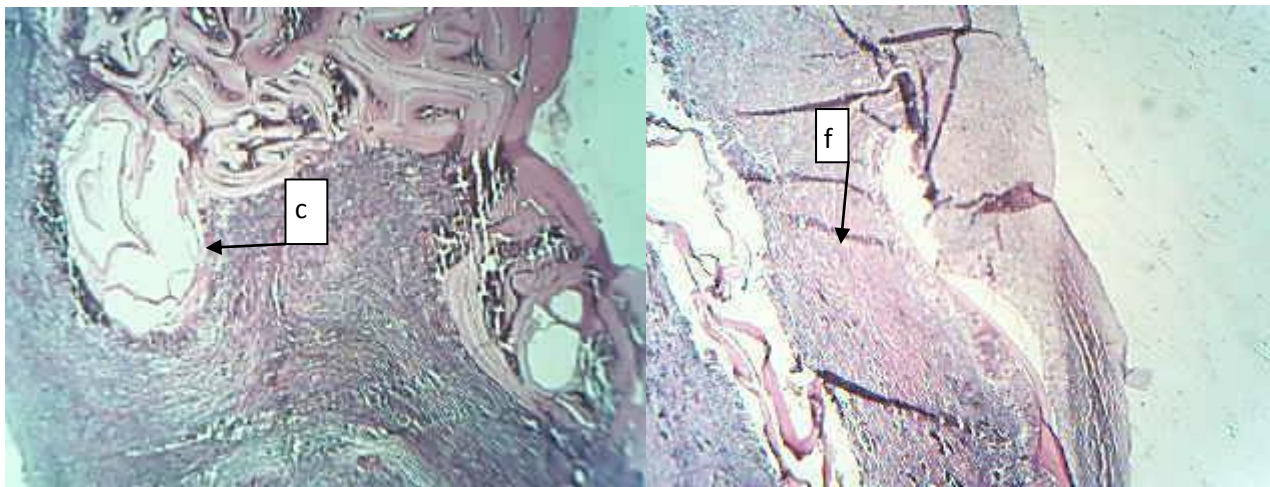
Pic. (6) thickened fibrous layer(f) and sever necrosis(n) of sterile cysts in sheep



Pic.(7) fibrous layer(f) and sever necrosis with eosinophilia(n) of fertile cyst in sheep



Pic.(8)fibrous layer with severe scattered of inflammatory cells with fibrous tissue(f) of fertile cyst in sheep



Pic.(9) (4X) extensive calcification(c) along hepatic tissue of sterile cysts in cow

Pic.(10) fibrous layer and sever necrosis with eosinophilia(f) of sterile cysts in cow

Discussion

The present study revealed that the presence of hydatid cysts in the liver of sheep and cows resulted in different histological lesions represented in inflammatory reaction, fibrosis and necrosis in the area near to the cysts. Such of these effects were mostly documented in different animals infected with different species of *Echinococcus*^{6,14,15}. In goat and sheep, Blanton *et al.* (1998)¹⁶ showed evidence of marked host cellular reaction consisting of infiltration of the adventitial layer with neutrophils, eosinophils, and plasma cells. In addition to this inflammatory infiltrate, the new space between the liver tissue and cyst wall contained disorganized fibroblasts and

mesenchymal cells. In the most necrotic areas, the laminate layer could not be collected together with adherent liver tissue and the adventitial layer appeared completely degenerated and it was replaced by acute inflammatory cells. Also, Ritter (1987)¹⁷ suggested that the liver cell necrosis may be either due to progressive action of intracellular enzymes of the injured cells or to a metabolic disturbance and inhibition of synthesis needed of DNA and hence protein synthesis. There is significant effect of amount of hydatid cyst which is higher in fertile cyst that contain alive and proliferated protoscolices which based on hydatid fluid components in nutritional requirements. The thickness of

fibrous and necrotic layer is significantly affect between sheep and cows due to different of defense mechanism and cellular effects with difference of animal species. In conclusion, echinococcosis is still an important health problem in Iraq that needs further study. The people traveling to endemic areas should be

educated not to contact with wild animals. There is a need for a suitable eradication program, so that untreated dogs as well as foxes, which play an important role in the contagiousness of the disease in rural areas, can be eradicated as an infectious agent.

References

- Lewis, J.W.; Koss, N. and Kerstein; M.D. (1975). A review of echinococcal disease. *Ann. Sug.*, 181: 390-396.
- Dent, C.R. and Kelly, J.D. (1976). Cestodes parasites of dog in central table land of New South Wales. *Aust. Vet. J.*, 52: 386-388.
- Baldock, F.C.; Thompson, R.A. and Kumaratilake, L.M. (1985). Strain identification of *E. granulosus* in determining origin of infection in a case of human hydatid disease in Australia. *Trans. Roy. Soc. Trop. Med. Hyg.*, 79: 175-180.
- Amman, R.W. and Eckert, J. (1996). Cestodes: *Echinococcus*. *Gastroenterol. Clin. North Am.*, 25:655-689.
- Schaefer, J.W. and Khan, M.Y. (1991). Echinococcosis (hydatid disease): lessons from experience with 59 patients. *Rev. Infect. Dis.*, 13: 243 - 247.
- Kebede, N. Mitiku, A. and Tilabun, G. (2009). Hydatidosis of slaughtered animals in Bahir Dar abattoir, northwestern Ethiopia. *Trop. Anim. Health Prod.*, 41(1): 43-50.
- Moro, P.L.; Gonzalez, A.E. and Gilman, R.H. (2000). Cystic hydatid diseases. In: *Hunter's Tropical Medicine and Emerging Infectious Disease*, 8th ed. (Stickland G. T.) W. E. Saunders Co. USA: 866-871.
- Gerazounis, M.; Athanassiadi, K.; Metaxas, E.; Athanassiou, M. and Kalantzi, N. (2002). Bronchobiliary fistulae due to echinococcosis. *Eur. J. Cardiothorac. Surg.*, 22: 306-308.
- Gutierrez, Y. (1990). *Diagnostic Pathology of Parasitic Infections with Clinical Correlations*. Philadelphia: Lea and Febiger., 460-480.
- Smyth, J. and Baret, N.J. (1980). Procedure for testing viability of human hydatid cyst following surgical, especially after chemotherapy. *trans roy soc trop med hyg* 74:5.
- Smyth, J.D. and Davies, Z. (1974). Occurrence of physiological strains of *Echinococcus granulosus* demonstrated by invitro culture of protoscolices from sheep and horse hydatid cyst. *Inf. J. parasitol.* 4:443- 445.
- SAS. (2001). *SAS users guide. Statistics version 6.12*. SAS institute, Inc, Cary, NC.
- Duncan, D. B. (1955). Multiple range and multiple F tests. *Biometrics*, 11: 1-42.
- Serefettin, M.; Merih, G.; Tulay, C. and Astarcioglu, H. (2003). The Pathology of Echinococcosis and the Current Echinococcosis Problem in Western Turkey (A Report of Pathologic Features in

- 80 Cases). Turk. J. Med. Sci., 33: 369-374.
15. Dai, W.; Waldvogel, A.; Silles-Lucas, M.; and Gottstein, B. (2004). *Echinococcus multilocularis* proliferation in mice and respective parasite 14-3-gene expression is mainly controlled by an $\alpha \beta ++$ CD4 T-cell-mediated immune response. Immunology, 112: 481-488.
16. Blanton, R.; Ernest, M.; Wachira, T.; Magambo, K.; Zeyhle, E.; and Schantz, P. (1998). Oxfendazole Treatment for Cystic Hydatid Disease in Naturally Infected Animals. Am. Soc. Microbiol., 42(3): 601-605.
17. Ritter, E. J. (1987). Altered Biosynthesis. In: Handbook of Teratology. Vol.2 Plenum Press, New York.

مقارنة عيانية ونسجية للإصابة بالأكياس العدرية في أكباد الأغنام والأبقار

منصور جدعان علي الخالدي
كلية الطب البيطري/ جامعة القادسية

مهند عبد الحسين حمزة السعداوي
كلية العلوم / جامعة المثنى

الخلاصة

تم اخذ عينات أكياس عدرية من أكباد أغنام (3 عينات عقيمة ومثلها خصبة) و3 عينات من الأكياس العقيمة في الأبقار مصابة من محلات القصابين في محافظة المثنى خلال شهر كانون الأول لسنة 2010. قيست أبعاد الأكياس وحسبت كمية وحيوية الرؤوس الأولية باستخدام صبغة الايوسين تحت المجهر الضوئي بالقوة X40. ثم أخذت مقاطع نسيجية لهذه الأكباد ولمسافات معينة وقرأ التأثير المرضي لهذه الأكياس على أنسجة الكبد وأكياس الصفراء. وجد أن النزف الحبري والشحوب في أكباد الأغنام المصابة بالإضافة للتكلس في أكباد الأبقار أهم الآفات العيانية المشاهدة أما الآفات النسيجية فقد لوحظت الطبقة الليفية السميكة وطبقة النخر وارتشاح الخلايا الحمضة والتكلس الواسع الشامل لكل أجزاء المنطقة المصابة في أكباد الأبقار المصابة. ظهر التأثير المعنوي في كمية السائل العدري وسمك الطبقة الليفية وسمك طبقة النخر.