

## Research article

### Toxic pathological effect of mitomycin-c on male reproductive organs in rat

Hala Abbas Naji

Khalil Gazar Chelab

Atiaf Ghanim Rhyaf

*Department of pathology and poultry diseases/College of Veterinary Medicine/ University of AL-Qadisiyah*

Corresponding Author Email: [Hala.abbas@qu.edu.iq](mailto:Hala.abbas@qu.edu.iq)

Co-Author Email: [Khalil.Chelab@qu.edu.iq](mailto:Khalil.Chelab@qu.edu.iq), [Atiaf.Ghanim@qu.edu.iq](mailto:Atiaf.Ghanim@qu.edu.iq)

(Received 24/8/2017, Accepted 25/12/2017)

#### Abstract

*The aim of present study was detected the effect of Mitomycin-c on the histological structure on male reproductive organ. In this study used (24) healthy adult male rats were divided into three groups, each group includes (8) animals: the 1<sup>st</sup> toxic group was injected (6.5mg/kg) of Mitomycin-c subcutaneous (s/c) once daily, the 2<sup>ed</sup> therapeutic or low dose group was injected (3.25 mg/kg) of Mitomycin-c subcutaneous (s/c) once daily, while the 3<sup>rd</sup> control group was injected physiological normal saline (0.9% NaCl<sub>2</sub>). The experimental period was (10) weeks. Animal, which were treated with Mitomycin-c along the period of experiment showed, sever pathological changes, particularly in testes and epididymis.*

**Keywords: Male reproductive organs, Mitomycin-c, Pathological effect, Rat.**

#### Introduction

For the 40 years ago, chemotherapy had helped in cancer management in humane and animal patients. More than 50 agent are beneficial in humane medicine, but the quantity of the partial use in veterinary medicine is smaller (1). Chemotherapy may controlling generalized rapidly progressive not receptively to surgery or radiotherapy or may help increment the disease-free interval after other initial treatment, it may prohibits spread of a neoplasm by controlling going early metastasis that are proliferation rapidly and have a comparatively small likelihood of containing resistant cells (2). In recent years, chemotherapy has gets a popular form of anticancer treatment, but it is often difficult to bring about because most of chemotherapy's useful agents are poisonous; this results from the look alike between cancerous cells and normal cells (3). Drug that kill tumors are not specific enough to leave normal cells unhurt. Therefore,

virtually all cancer chemotherapy is a susceptibly compromise between effectiveness and toxicity, resulting in significant side effects (4). Quinone-bunting alkylating agents are a kind of chemical agents that have received considerable interest as anticancer drugs since the late 1950<sup>s</sup>, therefore Mitomycin-c is a pattern of the highly active quinine-containing alkylating anticancer drug (6). The Mitomycin were first find out by (7), and Mitomycin-c was isolate by (8) from *Streptomyces caespitosus* in 1958. All are antibiotics effective against both Gram-positive and Gram-negative bacteria (7, 5), but only Mitomycin-C has marked anticancer activity. Mitomycin-C is given to medicating upper gastro- intestinal (e.g. esophageal carcinoma, anal cancer, breast cancer, besides by bladder instillation for superficial bladder tumors (8). The Mitomycin-C require intracellular activation

(6) by devaluation of the Mitomycin-c activate the a ziridine and carbamate alkylating groups and findings in the formation of DNA cross link which seem to be the primary mechanism for the antitumor effects of this agent (8). If oxygen is present, the reduced Mitomycin products can redox cycle to constitute reactive oxygen species. Interactive oxygen species damage cellular components, including DNA, spermatogenic

cell degeneration in the mature mammalian testis happens both spontaneously during normal spermatogenesis and in response to cytotoxic agents, Mitomycin-c is antibiotic that affects DNA synthesis (13). The aim of present study was to investigate some histopathological changes produced by toxicity of mitomycin-C (chemotherapeutic agent) on male reproductive system in rat.

## Material and Methods

### Ethical approval

The Animal Ethical Committee of Veterinary Medicine College, University of Al-Qadisiyah, Iraq, has approved the present study under permission No: 444

The present study was conducted on (24) white male rat of approximately the same age (8-10 weeks) and body weight (210 gram). The animals were housed in a 6\*4\*3 m<sup>3</sup> room in animal house, under 12 hours light / 12 hours dark cycle at 28±2°C for at least 1 week before the experiment, and these conditions were preserved until the end of the experiment. Animal cages were kept clean, food and water were given regularly every day. The animals were put as (8) rat in each standard plastic cages and this study continued for (6) weeks.

### Experimental Design:-

Rat were randomly divided into (3) equal groups (8) animals for each group, the dose of mitomycin-C was selected according to previous studies that demonstrated significant testicular toxicity (13).

## Results

The result of first group (toxic group) demonstrated severe vacuolation of Spermatogonia, marked atrophy of seminiferous tubules, reduced number of spermatocytes & degeneration of Leydig cell Figure(1) and Figure(2). Also in the present study, the testes in animals of toxic dose showed presence of spermatid multinucleated giant cells, degeneration of Leydig cells and

**First group:** - as toxic dose received (6.5 mg/kg) subcutaneous once daily.

**Second group:** - as a therapeutic (low dose) received (3.25 mg/kg) subcutaneous once daily.

**Third group:** - is control group received only normal saline (0.9 NaCl) subcutaneous once daily. For histopathology, pieces of 1-2 cm from testis and epididymis were taken then kept in 10% neutral buffered formalin for fixation, processed routinely in histokinette, cut at 5 Mm thickness by microtome (jung 4291, west Germany) and stained with haematoxylin and eosin stain then examined under light microscope (9).

### Treatment:-

Mitomycin-c (mitomycin-c kyowa) R is a crystalline mitomycin-c, vial of 10mg for injection subcutaneous, (India: kyowa Hakko Kogyo co. LTD., Japan). Each 10mg was dissolved in 500ml of distilled water to obtain solution included 0.02% mitomycin-c. Animals were injected once daily and for 6 weeks subcutaneous (3.25 mg/ kg B.W.). (10).

vacuolation of Spermatogonia Figure (3) & Figure (4). In addition, note one epididymal tubule showed empty from sperms and marked hyperplasia of epithelial cells Figure (5). In the second group (low dose group) the epididymis tubules of this group were demonstrated few contain sperms Figure (7&6)) The testes note complete spermatogenesis characterized by high

numbers of Spermatogonia, primarily & secondary spermatocyte with presence of sperm in lumen of seminiferous tubules

which showed compact and circulated Figure (8).

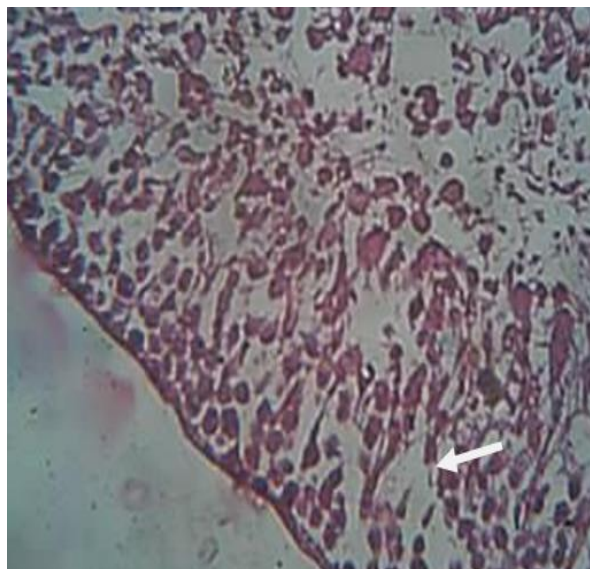


Figure (1): Testis. (First group), note marked atrophy of seminiferous tubules, vacuolation of Spermatogonia (arrows) and reduced number of spermatocytes & degeneration of leydig cells (arrows). 40X H&E.

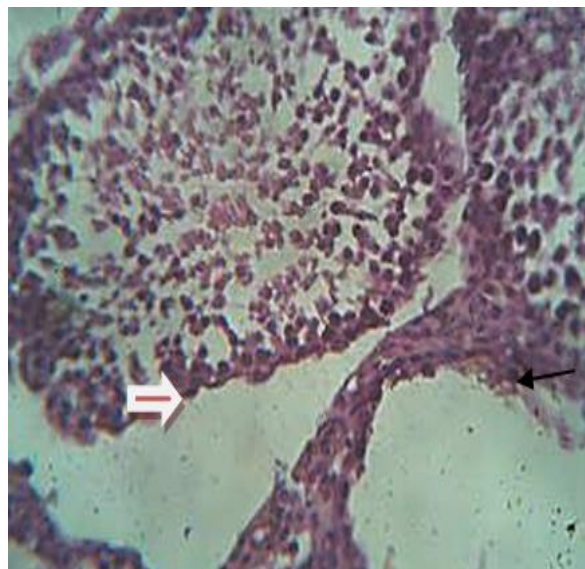


Figure (2): Testis. (First group), note severe degeneration of seminiferous tubules, vacuolation of Spermatogonia (arrows) and reduced number of spermatocyte. 40X H&E.

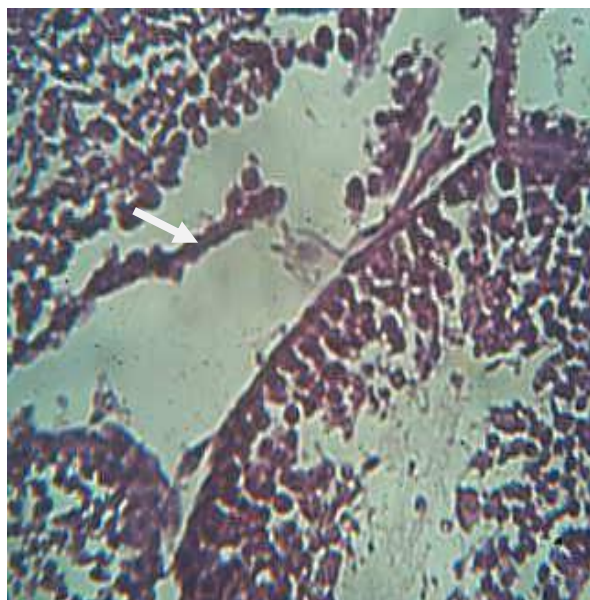


Figure (3): Testis. (First group), note degeneration of testicular tissue & presence of spermatid multinucleated giant cell (arrow). 40X H&E.

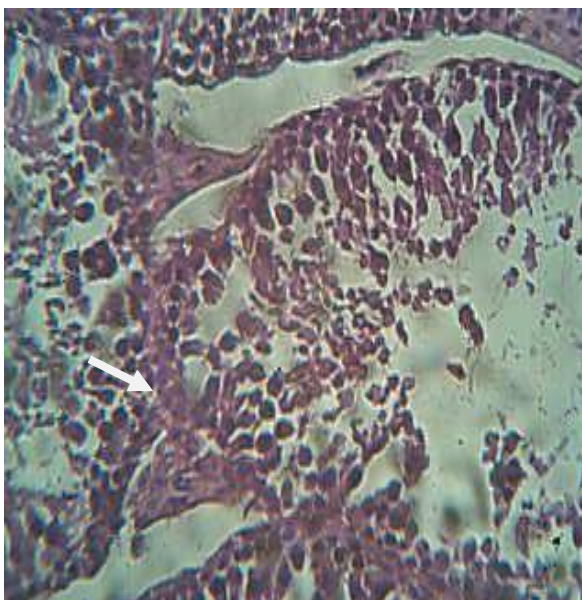


Figure (4): Testis. (First group), note degeneration of Leydig cells, vacuolation of Spermatogonia (arrow) & presence of spermatid multinucleated giant cell. 40X H&E.

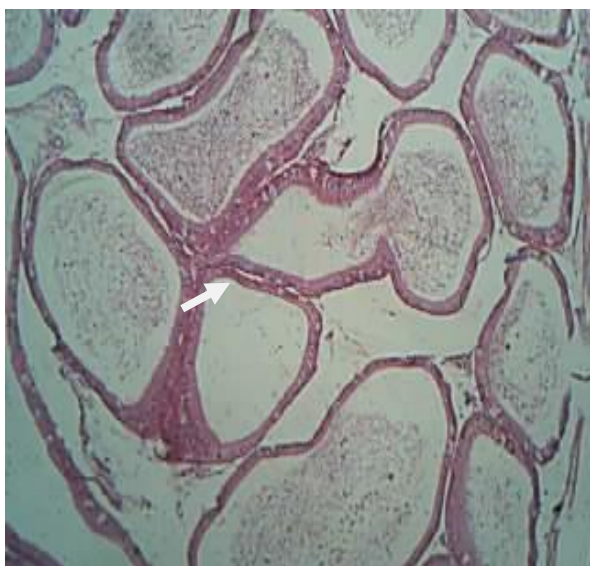


Figure (7): Epididymis. (Second group), note some epididymal tubules contain few sperms and the others were filled. (Arrow) 20X H&E.

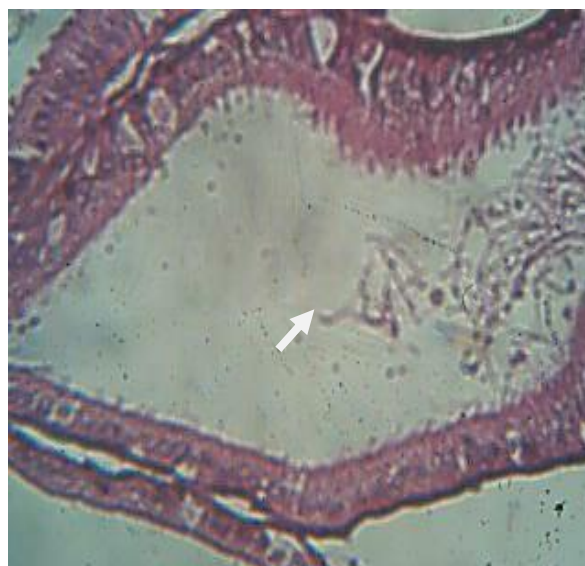

Figure (6): Epididymis. (Second group), there is note epididymal tubule contains few sperms hyperplasia of epithelial cells & presence of long steriocytes (arrows). 40X H&E

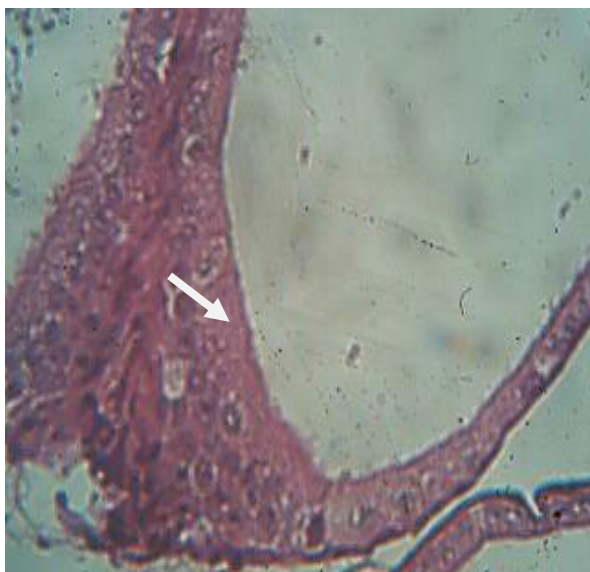


Figure (5): Epididymis. (first group), note one epididymal tubule showed empty from sperms (arrow). 40X H&E (end marked hyperplasia of epithelial cells)

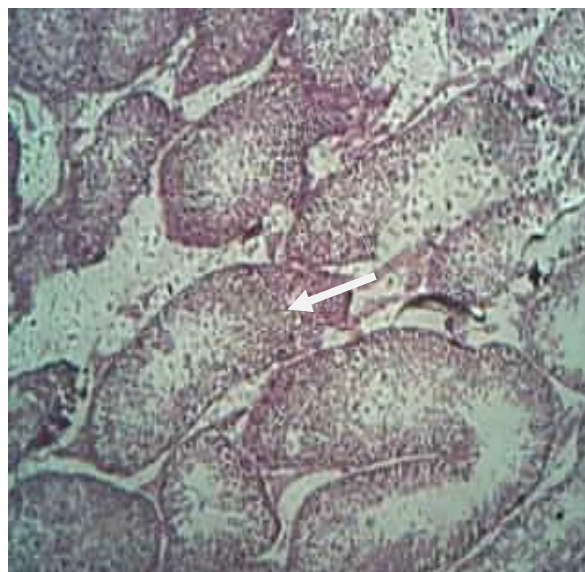

Figure (8): testes. (Second group), note complete spermatogenesis characterized by high numbers of Spermatogonia, primarily & secondary spermatocyte with presence of sperm in lumen of seminiferous tubules which showed compact & circulated (arrow) (arrow). 40X H&E.

## Discussion

Cancer happens when cells grow too rapidly & in an uncontrolled way. For cancer cells to grow, new DNA needs to be made. Mitomycin-c is a drug that is used to medicate certain cancers with mitomycin-c cancer cells

cannot make DNA; this kills cancer cells (17). However, mitomycin-c can also be harmful to other normal cells & organs in the body, this harmful effect is called mitomycin-c toxicity, using mitomycin-c for prolonged

which stays in the body, can increase the risk of toxicity (13). Therefore, the current study demonstrated that mitomycin-c considered as testicular toxicant to male reproductive system of male due to major histopathological changes, which showed in testes & epididymis. The testis were appeared affected in all treated animals especially in toxic dose group animals. The present study showed microscopic changes in testes & epididymis which characterized by evidence suppression of spermatogenesis which resulting in oligospermia (reduce in number of sperms) in all treated animals (therapeutic & toxic doses animals), it was reported by (11, 12), they reported that oligospermia may be occur due to long treatment of mitomycin-c. Also the result of toxic group demonstrated sever vaculation of spermatogonia due to degenerative process of seminiferous tubules and this reported by (14), they indicate that there is debilitating in seminiferous tubules due to taking high doses of mitomycin-c. Also in the present study,

the testes in animals of toxic dose showed presence of spermatid multinucleated giant cells. They are special cells indicate the degenerative process which occurring in seminiferous tubules. This result proved by (15), note presence of spermatid multinucleate giant cells in testes of rat due to long treatment of mitomycin-c. epididymis tubules of this group were demonstrated empty and not contain sperms due to inhibition of production of sperms (spermatogenesis) because epididymis is the pathway of sperms to outside from the testes in the intermediate dose ,toxicological changes were less previous group(14, 16). In testes, there is suppression of spermatogenesis & vaculation of spermatogonia, spermatozoa present in large numbers more than second group, also there was no presence of spermatid multinucleated giant cells .So the epididymal tubules contain few sperms others were filled this result proved by ( 17,12 ).

## References

- 1-Carter SK, Livingston RB. Drugs available to treat cancer. In Carter, S.K.:Principles of cancer treatment. McGraw, Hill.; New York. (1981).
- 2-Theilin GH. Chemotherapy. In Theilen GH, Madewell BR. Veterinary Cancer Medicine. 2 nd , Ed., Lea and Febiger, Philadelphia, (1987);pp 1315- 1318.
- 3-Boulton AJM, Carpenter JR, Clark B, Dascombe MJ, De akin JFM, Dive C, Duxbury AJ, Foster RW. Antiparasitic Chemotherapy. In Basic pharmacology. 4 th Ed., Oxford Auckland Boston and ohannesburg Melbourne, New Delhi, (1996);pp 269-274.
- 4-Danshiitsoodol N, de Pinho CA, Matoba Y, Kumagai T, Sugiyama M. "The mitomycin C (MMC)-binding protein from MMC-producing microorganisms protects from the lethal effect of bleomycin: crystallographic analysis to elucidate the binding mode of the antibiotic to the protein". *J Molec Biol* (2006);360 (2): 398–408.
- 5-Tomasz Maria. "Mitomycin C: small, fast and deadly (but very selective)." *Chemistry and Biology* (1995);2 (9): 575–579.
- 6-Renault J, Baron M, Mailliet P et al. Heterocyclic quinones 2. Quinoxaline-5,6-(and 5-8)-diones - Potential antitumoral agents. *Eur. J. Med. Chem.* (1981);16, 6, 545–550.
- 7-Hata TY Sano, R Sugawara, A Matsumae, K Kanamori, T Shima , T Hoshi. Mitomycin anew antibiotic from streptomycetes. *j antibiotic.* (1956);9,141-146.
- 8-Wakaki SH Marumo, K Tomioka, G Shimizu, E Kato, H Kamado, S Kuda, Y Fujimoto. Isolation of new fractions of antitumor mitomycins .Antibiotic chemother. (1958);8,228-240.
- 9-Luna LG. Manual of Histologic staining methods of the armed forces. Institute of Pathology. 3 rd ,Ed., McGraw-Hill Book Company, N.Y., Toronto, London, Sydney (1968);pp.12-31.
- 10-Chemwatch Material Safety Data Sheet.(2011). TCH 32647 C293LP Version

- No:6.1.1.1P:14 -19. [www.biochem.uci.edu/.../MSDS/Mitomycin%20C%20](http://www.biochem.uci.edu/.../MSDS/Mitomycin%20C%20).
- 11-Van VJ , deRooij DG,Wensing CJ, Bootsma AL.Protection of spermatogenesis against cytotoxic effects of two chemotherapeutic drugs by temporary testicular blood flow interruption in the arm . Sep.Oct, (1993);25(5):251-6.
- 12-Xiao Y, Tates AD. Increased frequencies of micronuclei in early spermatids of rats following exposure of young primary spermatocytes to acrylamide. Sep.(1994);309(2):245-53.
- 13-Soichi N, Chisato M. Detection of mitomycin c induced testicular toxicity by micronucleus in mice. Vol.(2), No.(2), (2003); 69-73.del:10.1046/j.1445-5781. 2003.00023.x.
- 14-Nakagawa S,Nakamura N, Fujioka M , Moric. Spermatogenic cell apoptosis induced by mitomycin c in the mouse testis Toxicol Appl pharmacol .Dec. (1997);147(2):204-13.
- 15-Sjoblom T, Parvinen M, Landetie J. Stage specific DNA synthesis of rat spermatogenesis an indicator of genotoxic effect of vinblastine ,mitomycin-c &ionizing radiation on rat spermatogonia & spermatocytes .Mutat Res .Oct.(1995);331(2):181-90.
- 16-Drews Jurgen. Drug discovery :Ahistorical perspective )Science (2000);287:1960-1964.
- 17-Ritter JM, Lewis LD, Mant TGK. Chemotherapy. A textbook of clinical pharmacology. 4th Ed., Hodder Headline Group, London;(1999);pp:555-558.